Spectroscopic Imaging as a Triage Test for Cervical Disease: A Prospective Multicenter Clinical Trial

Timothy DeSantis M.D.[1], Nahida Chakhtoura M.D.[1], Leo Twiggs M.D.[1], Daron Ferris M.D.[2], Manocher Lashgari M.D.[3], Lisa Flowers M.D.[4], Mark Faupel Ph.D.[5], Shabbir Bambot Ph.D.[5], Steven Raab M.D.[6], Edward Wilkinson M.D.[7]

[1]University of Miami, [2]Medical College of Georgia, [3]St. Francis Hospital—University of Connecticut, [4]Emory University, [5]SpectRx, Inc. [6]University of Pittsburgh, [7]University of Florida

Introduction

The present study was designed to assess the potential impact on cervical disease management that spectroscopic imaging would have if employed as a pre-colposcopy triage test. The study endpoints included both sensitivity to detect biopsy proven cervical dysplasia, especially moderate and severe forms (CIN2+), as well as specificity to rule out benign cervical conditions that also had been scheduled for colposcopy and biopsy. The study population included women with a history of abnormal cervical cytology or other risk factors, such as previously documented histopathology of cervical dysplasia in need of follow-up.

Objective

The objective of the study was to evaluate the potential safety and effectiveness of tissue spectroscopy for the diagnosis of cervical cancer in a prospective multicenter, IRB approved study of women scheduled for colposcopy on the basis of an abnormal Pap test or other risk factors.

Cervical Neoplasia Detection System (CNDS)

The device system (Guided Therapeutics, Inc. Norcross, GA, USA) used in the study is a nonsignificant risk device by FDA standards that noninvasively and automatically scans the ectocervix and distal endocervix for disease related changes in fluorescence and reflectance spectra (see Figure 1).

Alterations in fluorescence spectra are indicative of metabolic changes associated with neoplasia, while alterations in reflectance and scattering are indicative of structural changes associated with neoplasia, such as epithelial thickening, nuclear size and content and angiogenesis.[1,2,3,4]

Figure 1. CNDS Device

A plurality of equally spaced points over a one-inch diameter area of the cervix was automatically scanned during a four-minute period using a filtered xenon arc lamp as an illumination source.

For cervical tissue reflectance measurements, broadband spectral output ranging from about 350 to 900nm was automatically applied under software control to the cervix using the same xenon arc lamp. The resultant reflectance spectral output from the cervical tissue was imaged onto the CCD camera and stored for processing and analysis.

For cervical tissue fluorescence measurements, light from the arc lamp was band pass filtered to limit exposure of the cervix to bands within the 300 to 500 nm range. These spectral bands are known to excite fluorophores associated with neoplastic processes as described above. Each of the fluorescence wavelengths were applied automatically under software control in a predetermined order and scan pattern. The resultant fluorescent spectral output of the cervical tissue was imaged onto a charge coupled device (CCD) camera and stored for processing and analysis.

The system consists of two main physical components, the hand-held unit and the base unit (Figure 1). The handheld unit is connected to the base unit via fiberoptic cables for transmission of light to and from the base unit, which contains the xenon arc lamp, optical processing elements (e.g., filters and lenses) and the CCD camera on a rolling cart (CNDS Device).

The other major component of the CNDS is a computer for control and data processing. This includes the capability for a diagnostic algorithm based on spectroscopic information measured from the cervix, calibration data and other patient data, such as Pap results or patient demographic data.

Figure 2. Race Distribution

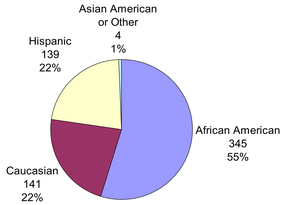

Table 1. Age Distribution

Category	Number	Percent
Median	27.7	--
Range	18-75	--
< Age 30	354	57.6
> Age 30	275	42.4

Methods

Subjects meeting the inclusion criteria underwent spectroscopy of the cervix during their colposcopy visit. Spectroscopy measurements taken over a four minute scan period were integrated by a cross-validated pattern recognition algorithm and compared with expert panel resolved histopathology to yield sensitivity and specificity of cervical spectroscopy. After the spectroscopy measurements were taken, a sample for Pap testing was taken, followed by colposcopy and biopsy, if indicated.

Histopathology Quality Control

Each clinical site fixed tissue per current clinical practice. An additional slide adjacent to the diagnostic slide was also cut and sent to the clinical pathology lab of one of the authors (EW). If EW disagreed with the diagnosis of the clinical site pathologist, the slide was then sent to a third pathologist (SR). A case was assigned to a diagnostic category when either the site and EW agreed or two out of three diagnoses agreed (i.e., either benign, CIN1, CIN2+, using the most severe disease grade for each case). A case was considered nonevaluable when all three pathologists disagreed.

Results

A total of 648 consecutive women from the four clinical sites met inclusion criteria, signed the consent form and were therefore eligible to participate in the study. Data could not be collected from 19 subjects because they withdrew before the study could be completed. Median age of the 629 study participants was 27.7 (range 18-75) and 354 (57.6%) were under the age of 30 at the time of the study. Three hundred forty-five characterized themselves as African American, 139 as Hispanic, 141 as Caucasian and 4 as Asian American or other. Demographic data are summarized in Figure 2 and Table 1. No adverse events were reported.

All women underwent colposcopic examination and all but 42 had a Pap test result and valid histopathology available. Of the 587 subjects that had valid Pap and histopathology and/or colposcopy results available, 15 cases could not be analyzed because of a device or operator error. Thus sensitivity and specificity of the test was calculated for the remaining 572 evaluable subjects (see Table 2).

Table 2. Sensitivity and specificity of spectroscopy by disease category for all 572 evaluable subjects.

All Cases (N = 572)	SENSITIVITY		SPECIFICITY*
Disease	CIN2+	CIN1	No CIN
Number Tested	142	180	250
Number Correct	135	135	138
Percent Correct	95.1	75	55.2
95% Confidence Interval	(91.55, 98.65)	(68.67, 81.33)	(49.04, 61.36)

* Note: In 149 cases, biopsy was not performed because expert colposcopy indicated a normal cervix and the Pap test did not indicate dysplasia. Most of these cases were referred to colposcopy on the basis of other risk factors and are categorized as benign for the purposes of statistical analysis.

Table 3. Sensitivity and specificity of cases with potentially interfering factors

	NUMBER			SENSITIVITY		SPECIFICITY
INTERFERING FACTOR	CIN2+	CIN1	No CIN	CIN2+	CIN1	No CIN
Excessive Ambient Light	4	10	6	100	50.0	16.7
Excessive Motion	4	12	10	75	70.0	70.0
Other*	1	7	8	100	57.1	25.0
Total	9	29	24	88.9	55.2	41.7

* Includes no or poor contact with cervix (n=5), poor centering, (n=2), excessive mucous and/or blood (n=9)

Sensitivity of cervical spectroscopy for CIN2+ lesions (n= 142) was 95.1% with a corresponding specificity for benign lesions (e.g., normal tissue, inflammation, metaplasia; n= 250) of 55.2%. The test also identified 75.0% of CIN1 lesions (n= 180) as positive. A secondary algorithm was employed to reduce the number of CIN1 lesions as positive by spectroscopy without a significant reduction in sensitivity for CIN2+ lesions.

Table 4. Sensitivity and specificity by disease category for 510 subjects with no interfering factors (unaffected cases).

All Cases (N = 510)	SENSITIVITY		SPECIFICITY*
Disease	CIN2+	CIN1	No CIN
Number Tested	133	151	226
Number Correct	127	119	128
Percent Correct	95.5	78.8	56.6
95% Confidence Interval	(91.98, 99.02)	(72.28, 85.32)	(50.14, 63.06)

* Note: In 135 cases, biopsy was not performed because expert colposcopy indicated a normal cervix and the Pap test did not indicate dysplasia. Most of these cases were referred to colposcopy on the basis of other risk factors and are categorized as benign for the purposes of statistical analysis.

Several potential confounding factors (e.g., mucous, blood, patient motion, ambient light) were examined to determine their potential impact on the accuracy of the test (see Table 3). Accidental levels of ambient light (e.g., strong examination light pointed directly at the lower genital tract) appeared to have the greatest effect, but no single factor contributed significantly to the results. When subjects with confounding factors were removed, no significant change in sensitivity or specificity was reported (see Table 4).

Color enhanced maps of the cervix could be constructed from the spectroscopic data (See Figure 3).

Figure 3. Cervical Maps
(Biopsy sites marked with Xs)

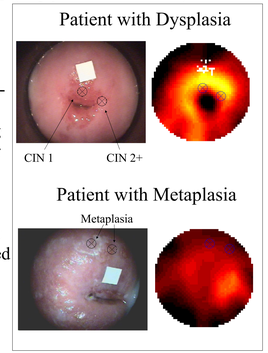

Summary and Conclusions

Spectroscopy of the cervix has the potential to accurately detect moderate and high-grade cervical dysplasia while also reducing the false positive rate for benign cervices. The test is relatively simple to implement, and as previously reported[5], was well accepted by subjects enrolled in the study. An additional strength of the test is its safety; it is noninvasive and no adverse events were reported. If the present results are validated in pivotal clinical trials and in commercial use, a significant reduction in the number of unnecessary follow-on tests, colposcopies and biopsies could be expected. The ability to utilize spectroscopic information for mapping cervical lesions could assist the physician in making biopsy and/or treatment decisions.

References

[1]Drezek RA, Richards-Kortum R, Brewer MA, Feld MS, Pitris C, Ferenczy A, et al. Optical Imaging of the Cervix. *Cancer (Supp.)* 2003: 98/9; 2015-2027.
[2]Richards-Kortum R. & Sevick-Muraca E. Quantitative optical spectroscopy for tissue diagnosis. *Annu Rev Phys Chem*. 1996;47:555-606.
[3]Tromberg B. Detection of cervical pre-cancer using reflectance spectroscopy. Presented at the Office of Women's Health Symposium on Biomedical Optical Diagnostics and Imaging. Washington, DC, October 1997.
[4]Ferris DG, Lawhead RA, Dickman ED, Holtzapple N, Miller JA, Grogan, et al. Multimodal hyperspectral imaging for the noninvasive diagnosis of cervical neoplasia. *J Lower Genital Tract Dis*. 2001;2:
[5]Ferris DG, Litaker MS, Dickman ED, Allmond LM, Smith KM, Arrington TL. Women's responses to cervical interrogation by fluorescent and reflective spectroscopy. *J Lower Genital Tract Disease*. 2003;7:299-303.

Supported in part by a grant from the National Cancer Institute.

CAUTION - Investigational device. Limited by federal law to investigational use. The availability of any product in the U.S. developed from these technologies is dependent on FDA marketing approval.

©2006 Guided Therapeutics, Inc.